

Usage of Er:YAG Lasers in Maxillary Sinus Surgeries: a Clinical Comparison of VSP vs Gaussian Profiles

Tosun Tosun¹, Stefano Benedicenti²

¹Ass. Prof. Dr. Dept. Surgical and Diagnostic Sciences, University of Genoa

²Prof. Dr. Dept. Surgical and Diagnostic Sciences, University of Genoa

ABSTRACT

The aim of the present retrospective study is to make a clinical comparison of Square Pulse Er:YAG versus Pulse Forming Network (PFN) Er:YAG lasers in maxillary sinus surgeries.

The Square Pulse group consists of 7 cases with 10 sinus lifting procedures. The Variable Square Pulse temporal profile producing Er:YAG device (LightWalker, Fotona) power settings were $400\text{mJ} \times 10\text{Hz} = 4\text{W}$, $50\mu\text{sec}$ pulse duration, 44% air, 33% water spray. In the PFN group, there were 6 cases with 9 sinus lifting procedures. The power settings of the PFN temporal profile producing device (VersaWave, Hoya ConBio) were $400\text{mJ} \times 15\text{Hz} = 6\text{W}$, $300\mu\text{sec}$ fixed pulse duration, under copious water/air cooling. The surgeon evaluated the clinical usefulness of the instruments by Visual Analog Scale according to the parameters of handling, visibility of the surgical field, irrigation, bone cutting speed, working time duration, scoring each on a scale from “poor” 0 (zero) to “perfect” 10. Membrane rupture rate was registered as either absent or present. The Square Pulse group showed only one membrane rupture and shorter preparation times.

According to the data collected during sinus surgeries, the VSP Er:YAG laser was found to be more effective in comparison to the PFN pumping laser.

Key words: dental implants, sinus floor augmentation, erbium-doped yttrium aluminum garnet lasers, laser therapy.

Article: J. LA&HA, Vol. 2014, No.1; pp.29-32.

Received: April 10, 2014; Accepted: May 22, 2014

© Laser and Health Academy. All rights reserved.
Printed in Europe. www.laserandhealth.com

I. INTRODUCTION

In dental implant applications “maxillary sinus floor augmentation” is aimed at obtaining adequate bone volume to place implants in the posterior maxilla, where residual bone height is reduced due to crestal atrophies.

Approaches to performing sinus lifts were initiated in late 70's [1-4]. During a maxillary sinus grafting technique, first described by Tatum in 1977 and published by Boyne and James in 1980, entrance was performed from the alveolar crest side [1, 5]. Tatum's first intention, rather than implant placement, was to obtain enough intermaxillary space for a removable prosthesis. He modified the crestal approach technique in 1986 by opening from the lateral sinus wall [6]. Similarly, Keller in 1987 offered procedural modifications by changing the sinus access to the lateral maxillary cortex [7]. Conventionally accepted methods include oval or rectangular entrance window designs. In earlier times, the lateral cortical wall, after preparation of the window corticotomy, was removed completely to the outside, but later, elevation of the membrane together with the bony wall through the inner sinus space became more popular. Another approach consists of a fracture of the upper border made by holes after osteotomies of the vertical and lower borders and translocation of the window wall through the sinus. The main point of these different approaches was to design lateral window borders by osteotomies to obtain adequate visibility of the operational field [8, 9].

The surgical instruments conventionally used to perform sinus grafting are rotary handpieces, where diamond round burs are incorporated [8, 9]. In the past decade, piezoelectric-ultrasonic devices have replaced rotary instruments for such purpose because of the reduced risk of membrane rupture [10]. Another alternative device to realize bone osteotomy is the Erbium-doped Yttrium-Aluminum-Garnet (Er:YAG) laser [11].

The Erbium laser (Er:YAG, 2940 nm wavelength) with its high absorption in water and low penetration depth in soft and hard oral tissues, enables high ablation depth control in bone surgery. This precise control offers a major advantage, especially in lateral approach sinus-grafting procedures, where often a thin bone wall is present. The pulse duration control offered by erbium lasers dramatically affects clinical results in terms of ablation capability [12]. Temporal profiles of dental Er:YAG lasers reveals that there are two distinct types of pulse profiles depending from the

technology utilized to energize pumping flashlamp: Square Pulse and Pulse Forming Network (PFN) [13]. The aim of the present retrospective study is to make a clinical comparison of Square Pulse Er:YAG versus PFN Er:YAG lasers in maxillary sinus surgeries.

II. MATERIALS AND METHODS

The study consisted of two groups. Seven patient with 10 sinus lifting procedures treated with an articulated arm Er:YAG device (LightWalker, Fotona), producing Variable Square Pulse (VSP) temporal beam profile, formed VSP group. Laser power settings used in PFN group were $400 \text{ mJ} \times 10 \text{ Hz} = 4 \text{ W}$, $50 \mu\text{sec}$ pulse duration, spray settings 4 air / 3 water. Six cases with 9 sinus lifting procedures where a fiber delivery Er:YAG device (VersaWave, Hoya ConBio, no available commercially since June 2011) was used formed PFN group. The power settings of the PFN group were $400 \text{ mJ} \times 15 \text{ Hz} = 6 \text{ W}$, $300 \mu\text{sec}$ fixed pulse duration, under manually controlled water/air spraying (45 ml/min water, $500 \text{ cm}^3/\text{min}$ air).

It was not possible to use the same power settings in both groups, as the laser device used in the PFN group was fixed to $300 \mu\text{sec}$. In the PFN group, the repetition rate was increased to 15 Hz , and 6 W of average power was needed to produce a similar ablation rate. Full-thickness flaps were raised after identification of the sinus wall. Bony window corticotomy was initiated by placement of the laser tip with 30° to 45° angulation to the cortical surface in a pseudo contact mode (with $0.5\text{--}1 \text{ mm}$ distance from the target tissue); lasing was started with slow movements and followed until observing the darkness of the underlying sinus cavity. Ablation was stopped after reaching the complete window borders decortication with very thin few bony bridges remaining on top of the Schneiderian membrane (Figs 1-6). The rest of the surgery was followed according to conventional sinus grafting techniques [6]. The surgeon evaluated the clinical usefulness of the surgical instruments by Visual Analog Scale (VAS) according to the parameters of handling, visibility of the surgical field, irrigation, bone cutting speed, working time duration, scoring each on a scale from “poor” 0 (zero) to “perfect” 10 (Table 1). The membrane rupture rate was registered as either absent or present.

Table 1: VAS score interpretation.

Score scale interpretation:		
0-4	poor	☹
5-7	moderate	☺
8-10	perfect	😊

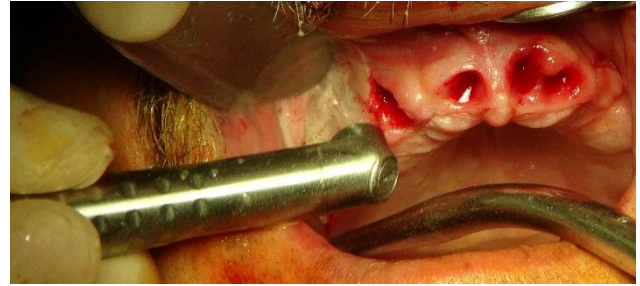


Fig. 1: Placement of laser tip by angle (VSP group)

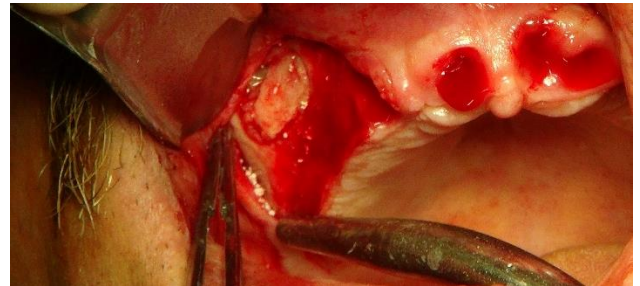


Fig. 2: Bony window prepared (VSP group)

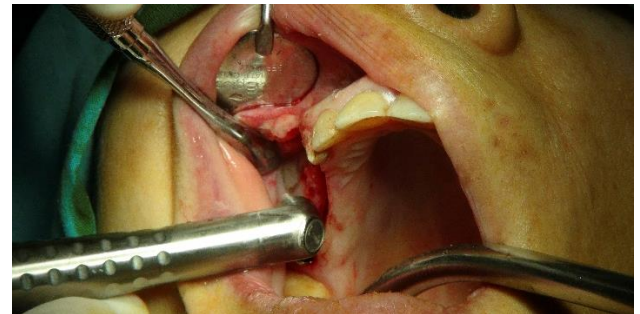


Fig. 3: Cortical bone ablation with pseudo-contact operating mode (VSP group)

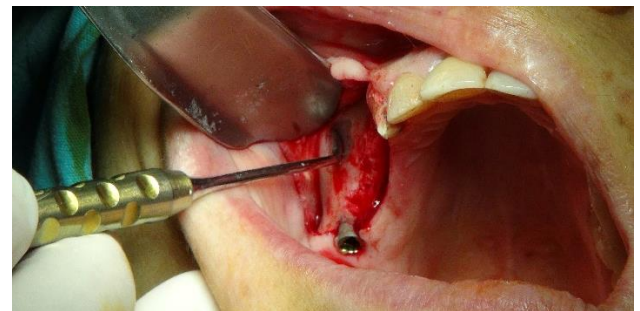


Fig. 4: After bony window preparation the surgery is followed by conventional sinus lifting procedures (VSP group)

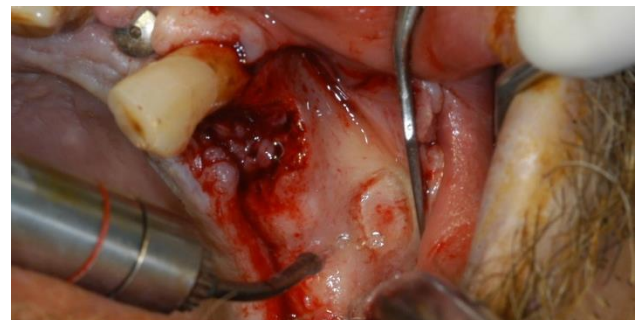


Fig. 5: Bony window preparation in the PFN group

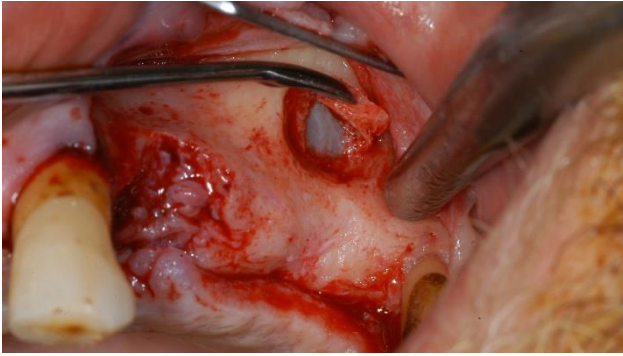


Fig. 6: Beveled window edges by angulated placement of laser tip (PFN group)

III. RESULTS

Scores according to the Visual Analog Scale were “perfect” in both groups for all parameters, except “working time duration,” which was found to be “moderate” in the PFN group. The time duration values were 9.7 and 6 respectively for the VSP and PFN groups.

Handpiece handling of the articulated arm and flexible fiber delivery system were found to be similar and both were scored “perfect”. Visibility of the operational fields were clear in both groups and were scored “perfect”. Cutting speed was scored “perfect” in both groups, with values of 9.9 in the VSP and 8 in the PFN group. The VSP group had one Schneiderian membrane rupture and the PFN group had two perforations in different patients.

Table 2: Er:YAG VSP group parameter scores.

case	site	handling	visibility	irrigation	cutting	time
1	1	9	9	10	10	9
2	2	9	9	10	10	9
3	3	10	10	10	10	10
4R	4	10	10	10	10	9
4L	5	10	10	10	10	10
5R	6	10	10	10	10	10
5L	7	10	10	10	10	10
6	8	10	10	10	9	10
7R	9	10	10	10	10	10
7L	10	10	10	10	10	10
Mean		9.8	9.8	10	9.9	9.7
Comment		perfect	perfect	perfect	perfect	perfect

Table 3: Er:YAG PFN group parameter scores.

case	site	handling	visibility	irrigation	cutting	time
1	1	10	9	10	8	6
2	2	9	9	10	8	7
3	3	9	9	10	8	7
4R	4	10	10	10	8	7
4L	5	9	10	10	8	7
5R	6	9	9	10	7	4
5L	7	8	8	10	7	4
6R	8	10	10	10	9	6
6L	9	10	10	10	9	6
Mean		9.33	9.33	10	8	6
Comment		perfect	perfect	perfect	perfect	moderate

IV. DISCUSSION

Stübinger et al. [11] used $1000 \text{ mJ} \times 12 \text{ Hz} = 12 \text{ W}$, and $300 \mu\text{sec}$ pulse duration power settings for a sinus lifting procedure irradiating around a metal template by keeping the pilot beam at right angle to the bone surface and reported that the applied laser parameters did not seem to be practicable for any clinical sinus elevation procedure. They concluded that missing depth control resulted in uncontrollable, severe damage to the underlying membrane. In our study, we used less energy (400 mJ) and managed the control of ablation by placement of the laser tip at a certain 30° to 45° angle to observe and control the depth of decortication (Figs 1-6). By inclined approach to the bone surface it was possible to clearly notice the ablation of bone tissue layer by layer and to avoid the sinus membrane rupture/perforation related to the poor depth control which is one of the major disadvantage of laser-assisted sinus floor elevation surgery.

In our study, cutting speed was higher in the VSP device even though the power was lower than in the PFN group. The short pulse duration in the VSP group enables the laser to produce high peak power. The limitation of the PFN device is that there are no options in terms of pulse durations. The PFN device used was fixed to $300 \mu\text{sec}$ pulse duration. With 400 mJ of energy, the PFN device produce 1.33 kW of peak power, whereas the VSP group with 400 mJ energy reached 8 kW of peak power. The ablation rate of hard tissues with the $300 \mu\text{sec}$ pulse duration was less than the ablation obtained with $50 \mu\text{sec}$ pulse duration.

The Visual Analog Scale (VAS) scores between the groups were similar as shown in the tables, but with noticeable differences in bone-cutting speed and working time duration to the advantage of the VSP group (Fig 7).

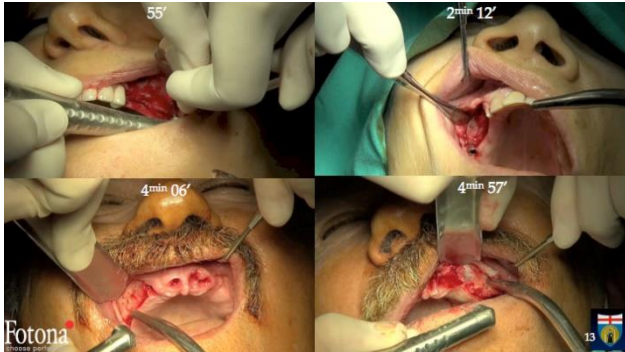


Fig. 7: Bony window preparation of Square Pulse group varied between 55seconds to 4:57minutes

The handling of the articulated arm for an experienced surgeon was similar to the flexible fiber delivery system. Thus, there were no evident differences between both delivery methods.

The visibility of the operational fields was clear in both groups due to the copious water irrigation and air spray. The only detail to mention is that with the Square Pulse device, it was possible to digitally quantify the amount of water and air, whereas in the Gaussian device it was manually adjusted without measurement.

Schneiderian membrane ruptures depend on various factors, such as operative trauma, previous sinus interventions and traumas, and chronic infection of the sinus. Ruptures may be related not only to the operative skills of the surgeon but also to a host of factors. Although a careful approach was taken, there were membrane perforations in one case in the VSP and in two cases in the PFN group.

V. CONCLUSIONS

The usage of erbium lasers to prepare a lateral bony access window in sinus lifting procedures was found to be reasonable. Effectiveness in bone cutting, while maintaining a clear operational field of vision due to the air and water spraying are advantageous points of erbium lasers. A short pulse-duration modality creates an advantage in terms of operation time. According to the data collected during sinus surgeries, the VSP Er:YAG laser was found to be more effective in comparison with a fixed pulse-duration PFN pulse laser.

ACKNOWLEDGMENT

This research was carried out in a collaboration with the EU regional Competency Center for Biomedical Engineering (www.bmecenter.com), coordinated by Laser and Health Academy (www.laserandhealthacademy.com), and partially supported by the European Regional Development Fund and Slovenian government.

REFERENCES

1. Tatum 1977: Smiler D, Johnson P, Lozada J, Misch C, Rosenlicht J, Tatum H, Wagner J. Sinus lift grafts and endosseous implants: Treatment of the atrophic posterior maxilla. *Dent Clin North Am* 1992;36:151–188.
2. Chanavaz M. Maxillary sinus: Anatomy, physiology, surgery, and bone grafting related to implantology—Eleven years of surgical experience (1979–1990). *J Oral Implantol* 1990;16:199–209.
3. Misch CE. Maxillary sinus augmentation for endosteal implants: Organized alternative treatment plans. *Int J Oral Implantol* 1987;4:49–58.
4. Smiler D, Holmes R. Sinus lift procedure using porous hydroxyapatite: A preliminary report *J Oral Implantol* 1987;13:239–253.
5. Boyne PJ, James RA: Grafting of the maxillary sinus floor with autogenous marrow and bone. *J Oral Surg* 1980;38:613.
6. Tatum H. Maxillary and sinus implant reconstruction. *Dent Clin North Am* 1986;30:207–229.
7. Keller EE, Van Roekel NB, Desjardins RP, Tolman DE. Prosthetic–surgical reconstruction of the severely resorbed maxilla with iliac bone grafting and tissue-integrated prostheses. *Int J Oral Maxillofac Implants* 1987;2:155–165.
8. Jensen OT, Shulman LB, Block MS, Iacono VJ. Report of the sinus consensus conference of 1996. *Int J Oral Maxillofac Implants* 1998;13 Suppl:11–45.
9. Geurs NC, Wang IC, Shulman LB, Jeffcoat MK. Retrospective radiographic analysis of sinus graft and implant placement procedures from the Academy of Osseointegration Consensus Conference on Sinus Grafts. *Int J Periodontics Rest Dent* 2001;21:517–523.
10. Delilbasi C, Gurler G. Comparison of piezosurgery and conventional rotative instruments in direct sinus lifting. *Implant Dent* 2013;22:662–5.
11. Stübinger S, Nuss K, Sebesteny T, Saldamli B, Sader R, von Rechenberg B. Erbium-doped yttrium aluminium garnet laser–assisted access osteotomy for maxillary sinus elevation: a human and animal cadaver study. *Photomedicine and Laser Surgery* 2010;28:39–44.
12. Lukac M, Marincek M, Grad L. Super VSP Er:YAG pulses for fast and precise cavity preparation. *J Oral Applications* 2004;4:171–173.
13. Nemes K, Lukac M, Mozina J. Variable square pulse vs conventional PFN pumping of Er:YAG laser. *Optics & Laser Tech* 2012;44:664–668.

The intent of this Laser and Health Academy publication is to facilitate an exchange of information on the views, research results, and clinical experiences within the medical laser community. The contents of this publication are the sole responsibility of the authors and may not in any circumstances be regarded as official product information by medical equipment manufacturers. When in doubt, please check with the manufacturers about whether a specific product or application has been approved or cleared to be marketed and sold in your country.